with liver or kidney disease, Parkinson's disease, depression, or trimethylaminuria may be at an increased risk of adverse events when consuming choline at a level up to or near the upper limit, though otherwise there is no known toxicity of choline to humans.[7,57] It is regarded as likely to be safe in pregnancy and lactation when the upper limit is not exceeded.[52]

Pantethine is exceptionally well tolerated at doses up to 1200 mg.[5,47–51,53,54] The most common side effects are gastrointestinal in nature and include nausea, diarrhea, and epigastric discomfort. When using doses in excess of 1200 mg, monitor closely and down titrate or discontinue when necessary for side effect control. There is insufficient evidence to support the safety of its use in pregnancy and lactation and should therefore be avoided.[53] There is no known toxicity to humans even at very high levels of intake.[5,53]

Patient Data

We have used the MAP protocol to address tachyarrhythmias, including atrial fibrillation, ectopic rhythms, and palpitations. In the upcoming months, we will publish a peer-reviewed case series on the success of the use of MAP in patients with these conditions. A small sampling of successful case data will be discussed here and is summarized in Table 2.

Case 1

C. F., a 44-year-old female, presented to clinic with complaints of palpitations, pounding heart, and rapid heart rate. Occasional "flip-flop" sensations in her heart had occurred for more than 10 years, but had increased in frequency to every 30 seconds over the previous two weeks. Her physical exam was normal across seven systems. Her electrocardiogram (ECG) revealed an accelerated junctional rhythm, diffuse nonspecific ST segment changes, and no arrhythmic beats (Figure 2A). Blood chemistries and thyroid lab tests were within normal limits. MAP was initiated at 1000 mg of pantothenic acid and two tablespoons soy lecithin mixed in water and used daily.

One week later, the patient reported noticing a reduction in heart rate within three minutes of her initial use of the MAP. She was still having occasional palpitations but much less frequently and lasting only 10 seconds; she had not been using the MAP daily. Her ECG on that date was normal, demonstrating a sinus rhythm at a rate of 60 bpm and no ST changes (Figure 2B). The patient was reminded to use the MAP on a daily basis and was maintained at stage 1.

One month after the initial visit, the patient reported only one episode of palpitations over the previous two week period which lasted less than one minute in duration. Overall, she was pleased and thought that the treatment plan had been effective.

Case 2

X. C., a 29-year-old male, presented with complaints of palpitations lasting approximately 30 seconds and occurring every other day up to 2 to 3 times daily for the previous 10 months. They felt like early, strong, or pounding beats in his chest and neck that gave him a "dropping" feeling in his chest. An exercise stress test revealed premature atrial contractions (PACs) in patterns of bigeminy and quadrigeminy,13 PACs per minute, an ectopic atrial pacemaker, and inappropriate blood pressure response to exercise.

The patient reported daily use of a B vitamin complex and 1 gram of essential fatty acids. The MAP stage 1 was initiated using pantethine 500 mg and choline bitartrate 2000 mg along with B complex twice daily, a botanical formula (two parts each *Passiflora incarnata* and *Crataegus oxycantha*, one part each of *Valeriana officinalis* and *Leonorus cardiaca*), 2 mL three times/day, and magnesium glycinate 480 mg/day.

One week later, he reported noticing improvements after the first three days of treatment. He was feeling fewer palpitations and less anxiety in stressful situations, but was still having 1 or 2 symptomatic palpitations after daily exercise. The MAP was increased to stage 2 and no other changes were made to the treatment plan.

At two-week follow up, the patient reported that his palpitations had improved further, but were not yet completely gone. He still noticed palpitations if he did not get enough rest. Their quality and severity had decreased; he now reported them as "very subtle." Stage 2 MAP was maintained.

At follow-up two weeks later, the patient reported that he had not been having palpitations. Cardiac monitoring for heart rate variability revealed no arrhythmic beats.

Case 3

G. S., a 59-year-old female, presented with "flutters" after receiving "a lot of epinephrine" during a dental procedure 3 months prior. Immediately after the procedure she began experiencing "strong and weak flutters" that could last a week or more. The severity of her palpitations had decreased somewhat over the three

➤

(A) 12 lead ECG demonstrating accelerated junctional rhythm with ST changes.

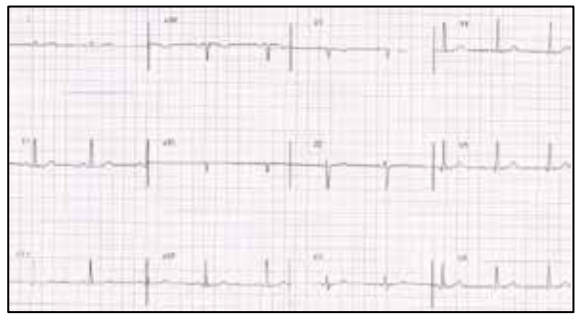

(B) Normal 12 lead ECG demonstrating normal sinus rhythm and resolution of ST changes.

Figure 2: 12 lead electrocardiograms for Case 1 – 44-year-old female before (A) and after (B) MAP treatment.